

**PITUITARY CELLS IN MAN DURING AGING:
AN IMMUNOHISTOLOGICAL AND MORPHOMETRIC STUDY****ĆELIJE HIPOFIZE KOD ČOVEKA TOKOM STARENJA:
IMUNOHISTOLOŠKA I MORFOMETRIJSKA STUDIJA**

Jovana Čukuranović Kokoris, Braca Kundalić, Miljana Pavlović, Sladjana Ugrenović

University of Niš, Faculty of Medicine, Department of Anatomy, Niš, Serbia

Summary

Background: Aging is a multifactorial process, which inevitably leads to numerous changes in the life of each individual. As the lifespan of people around the world has increased, scientists began to study the mechanisms that would enable high-quality and safe aging. In this review, the focus is on showing the effect of aging on the characteristics of pituitary cells.

Methods: In order to write this review, we undertook an electronic literature search through the PubMed and Google Scholar databases using the terms aging, histological, ultrastructure of pituitary cells, also using the »related articles« option. We also analyzed authored and co-authored articles, which were necessary for this type of publication.

Results: This review article describes the immunohistological, ultrastructural and morphometric characteristics of adrenocorticotrophic (ACTH), somatotrophic (GH), gonadotrophic (LH) and folliculostellate (FS) pituitary cells during aging, in young (about 47 years) and old (over 70 years) human cadavers.

Conclusions: The described immunohistological and morphometric characteristics of pituitary cells in this review showed that the volume density of ACTH, GH and LH cells was statistically increased ($p < 0.05$) in old cadavers, which indicates an attempt by these cells to bring the pituitary gland to a relatively balanced state.

Keywords: ACTH cells, GH cells, LH cells, FS cells, aging

Kratak sadržaj

Uvod: Starenje je multifaktorski proces, koji neminovno dovodi do brojnih promena u životu svakog pojedinca. Kako se životni vek ljudi širom sveta produžio, naučnici su počeli da proučavaju mehanizme, koji bi omogućili kvalitetno i bezbedno starenje. Cilj pregleda je da ukaže na promene u ćelijama hipofize izazvane procesom starenja.

Metode: Za pisanje ovog pregleda korišćena je elektronska pretraga literature kroz baze podataka PubMed i Google Scholar sa terminima starenje, histološki, ultrastruktura ćelija hipofize, a korišćena je i opcija »srodni članci«, kao i dodatna analiza autora i koautora članaka koji su neophodni za ovu vrstu publikacije.

Rezultati: U ovom preglednom članku opisan je uticaj starenja na imunohistološke, ultrastrukturne i morfometrijske karakteristike folikulostelatnih (FS), adrenokortikotropnih (ACTH), somatotropnih (GH) i gonadotropnih (LH) ćelija hipofize, kod mladih (oko 47 godina) i starih (preko 70 godina) ljudskih leševa.

Zaključak: Opisane imunohistološke i morfometrijske karakteristike ćelija hipofize u ovoj reviji, ukazuju na značajno povećanje zapreminske gustine ACTH, GH i LH ćelija kod starih kadavera, što je pokazatelj pokušaja ovih ćelija da dovedu hipofizu u kakvu-takvu ravnotežu.

Ključne reči: ACTH ćelije, GH ćelije, LH ćelije, FS ćelije, starenje

Address for correspondence:

Jovana Čukuranović Kokoris PhD
Department of Anatomy, Faculty of Medicine
University of Niš
Bulevar Dr Zorana Đinđića 81, 18000 Niš, Serbia
Mob. Tel. +381 64 529 55 76
e-mail: jovana.cukuranovic.kokoris@medfak.ni.ac.rs

Introduction

The pituitary gland represents a structural and functional link between the two main regulatory integration systems of the human body - nervous and endocrine. The pituitary gland is an endocrine gland that controls almost the entire endocrine system and affects the growth, metabolism, stress response, and reproduction of the organism (1). The glandular part is represented by the adenohypophysis, while its nervous part is the neurohypophysis (2). Adenohypophysis makes up about 75% of the entire gland and consists of the distal, intermediate, and tuberal parts. The intermedial and tuberal parts are stunted in humans, so endocrine activity is almost exclusively associated with the *pars distalis* of the adenohypophysis (3). Cells that produce hormones that secrete adrenocorticotrophic hormone (ACTH), thyroid stimulating hormone (TSH), gonadotropic hormones (follicle stimulating hormone-FSH and luteinizing hormone-LH), growth hormone (GH), prolactin (PRL) and human chorionic gonadotropin (hCG) are located in the distal part of the pituitary gland (1). The *pars intermedia* in humans is very poorly developed and makes up only 2% of the pituitary gland. It is made up of cells that secrete melanostimulating hormone (MSH) and folliculostellate cells (4). MSH cells are large and polygonal (5). The granular endoplasmic reticulum (gER) is poorly developed and consists of individual, rare, narrow cisterns. Cisternae, vesicles and vacuoles are differentiated in the Golgi zone, and few mitochondria are elongated (6). The *pars tuberalis* is a small area around the infundibulum of the pituitary gland. Epithelial cells in this sheath are folliculostellate cells (4). Alpha-Melanocyte-stimulating hormone (α -MSH) is involved in melanogenesis (7).

Aging is a multidimensional process that involves changes in the interaction of social, psychological, cognitive and genetic aspects (8). Many works point to the fact that with aging, there are structural changes in ACTH cells, gonadotropic LH cells and somatotrophic cells of the adenohypophysis of humans and animals, which can lead to the aforementioned hormonal dysfunction (9–15). In different people, aging processes are significantly different, and they are conditioned by life habits and environmental factors (16). Physiological changes in the functioning of the hypothalamus and pituitary gland (HP) are responsible for the mechanism of biological aging (10). A large number of studies indicate that with aging, the hypothalamic–pituitary–adrenal axis (HPA) system becomes more sensitive to stressors and that its return to normal functioning is slower (17). In addition to the HPA axis, significant changes occur in the functioning of the gonadotropic and somatotrophic axes (18, 19). The term gonadopause (18) generally describes a decrease in the bioavailability of sex hormones, while the term somatopause (19) describes a progressive decline in

the bioavailability of GH and/or insulin-like growth factor 1 (IGF-1).

Although the role of the pituitary gland is essential for the balanced functioning of the organism, there are few studies dealing with the structural changes of pituitary cells during aging (7).

Ontogeny of ACTH, GH, FSH, LH, and FS cells during aging

ACTH cells were immunocytochemically detected within Rathke's diverticulum, while the concentration of ACTH was determined by radioimmunoassay in fetal blood up to the eighth week of gestation. ACTH-positive cells appear after 21 weeks of gestation in the middle part of the human fetal pituitary gland (20). In the anterior pituitary of adults, ACTH makes up between 10% and 20% of the cell population and can be single or in groups (10, 21). These cells synthesize the precursor molecule ACTH known as proopiomelanocortin (POMC), from which the following are produced by the action of proteolytic enzymes within corticotrophs: β -lipotropic hormone (LPH), β -endorphin, ACTH, enkephalin and melanocyte-stimulating hormone (MSH) (10).

Secretion of pituitary GH cells increases during gestation and decreases in the neonatal period due to the activation of the negative feedback mechanism by increasing concentrations of IGF-1 (22). GH secretion remains stable during childhood, increases during puberty, and then decreases during adulthood (23). The level of circulating GH after 30 years of age decreases by 1% per year so that in older men, the release of GH can be 5 to 20 times lower than that in younger adults (24), indicating that GH production decreases by 14% every ten years; therefore, the deficiency of this hormone can be over 35% in men aged 60 years. The level of GH in people older than 70 years is significantly reduced and is approximately 1/3 of the recorded values at puberty (25). The causes and mechanisms responsible for the development of late hyposomatotropism, i.e. somatopause, have not been sufficiently studied and described in the literature. Decreased GH secretion during aging is thought to result from a combination of decreased secretion of GH-releasing hormone (GHRH) or ghrelin (26) as well as excessive secretion of somatostatin (SRIH) (27). All these factors lead to a reduced amount of secreted GH per secretory impulse. Aging does not change the frequency of pulsatile GH secretion, nor does it affect the basal secretion of GH and its half-life, nor the kinetics of its elimination (28). Changes in GH secretion with aging are partly due to specific structural changes at the level of the hypothalamus (29) but also to some insufficiently studied factors that affect the somatotropes of the adenohypophysis (30). The consequences of somatopause are reflected in the appearance

of intra-abdominal obesity, osteoporosis, insulin resistance, hyperlipidemia, risk of atherosclerosis and cardiovascular diseases (31). Since the clinical signs of late hypogonadism and hypsomatotropism significantly overlap, some authors believe that they are the result of a common pathophysiology, i.e. that the decrease in GH/IGF-1 secretion is the result of decreased androgen secretion that decreases with age and decreases hypothalamic-pituitary GH function/IGF-1 axis (32).

Gonadotropic cells (FSH and LH) in humans make up 7–15% of the distal part of the pituitary gland (33). In the fetal hypothalamus, gonadotropin releasing hormone (GnRH) is present from 6 weeks of gestation (34). Measurable amounts of LH and FSH in the fetal pituitary are up to 10 weeks, and the first circulating gonadotropins in the human fetus have been observed up to 12–14 weeks of gestation (35). In the serum, the highest levels of FSH and LH are detected around 20 weeks (36). The concentration of these hormones decreases in the second half of pregnancy, triggering negative feedback mechanisms, increasing maternal estrogen, as well as the secretion of sex steroids by the fetal gonads (34). Postnatal serum LH and FSH levels peak at around 2–3 months of age and then return to the prepubertal level at about 6 months of age in boys and 1–2 years of age in girls (37). During childhood, gonadotropin concentrations do not change until the onset of puberty, while serum LH and FSH levels increase during puberty (38). Due to changes in the functioning of the hypothalamus-pituitary-gonadal axis a decrease in testosterone levels was found in older men both due to testicular anomalies and higher basal levels of LH and FSH (39). Serum testosterone concentration in men older than 70 years progressively decreases by almost 25% (40). Due to disturbances in the functioning of the hypothalamus-pituitary-gonadal axis, due to reduced secretion of gonadotropin-releasing hormone (GnRH), occurs gonadopause (late hypogonadism) (12, 41). Late hypogonadism is characterized by abdominal obesity, reduced beard growth, bone and muscle mass (42). In addition to the mentioned typical characteristics of hypogonadism, there are also numerous non-specific symptoms such as depression, memory loss, nervousness, insomnia, temporary hot flashes or sweating, as well as a loss of sexual desire (18). The daily rhythm of testosterone secretion, observed in younger men, may be reduced or lost in older men (40). The bioavailability of free testosterone in relation to total testosterone decreases with age because the level of globulins that bind sex hormones decreases (39). Decreased serum testosterone concentrations due to age are mainly due to reduced production, as its plasma clearance rates are lower in older men than in younger men due to the combined effects of medications, comorbid conditions, and intercurrent diseases (43). In older

men, established lower testosterone concentrations are mostly associated with preserved, and sometimes increased, but irregular LH secretion (44). The causes of dysregulated LH secretion in older men and testosterone release are still unclear. One reason may be impaired testosterone feedback efficiency due to reduced expression of androgen receptors in the brain and pituitary gland (27). Synthesis and secretion of LH are, in addition to central regulation, also under the control of various signalling molecules involved in paracrine/autocrine control of gonadotropic function (45). Gonadotropes interact with the hormone-producing GH, ACTH, and PRL cells of the pituitary gland (11), as well as with non-hormonal cells such as folliculostellate cells (17).

Immunohistological characteristic of ACTH, GH, LH, and FS cells in cadavers during aging

Immunopositive ACTH cells are oval, polygonal or star-shaped, brown, with a pronounced cytoplasm. The nuclei are euchromatic, eccentrically located, spherical or irregular. These cells are mainly located in the central, mid-sagittal region, less so in the wings of the distal part of the pituitary gland and only occasionally in the tuberal region. In the glandular acinus of young men, ACTH cells are negatively stained with small clusters of positively labelled single cells in between (*Figure 1*) (10). Immunopositive ACTH cells of the middle wedge of the distal pituitary gland in older cases are more numerous than in young cases. ACTH cells are distributed in oval structures or larger irregular groups (10). Ultrastructural analysis showed that secretory granules with a diameter of 200–350 nm are distributed along the cell membrane. The granular endoplasmic reticulum (gER) is poorly developed in contrast to the well-developed Golgi complex. A few mitochondria are rod-shaped, with transverse cristae (6).

Somatotropic cells of younger corpses are more prominent in the lateral wings of the adeno-hypophysis than in the intermedial part. They are predominantly polygonal in shape with an eccentric euchromatic nucleus, and immunopositivity is observed in the cytoplasm (14) (*Figure 1*). In older cases, there are significantly fewer somatotropes in the intermediate part and lateral wings of the adeno-hypophysis. The cells showed a slightly stronger immunopositive response in the pars intermedia of the adeno-hypophysis (14). Earlier immuno-electron-microscopic studies of the rat pituitary showed that GH cells are pyramidal, usually in groups, in close contact with blood capillaries (46). According to the size of the secretory granule, rat GH cells are divided into three types. Type I GH cells contain large secretory granules (diameter 250–350 nm) and are numerous after birth and up to 6 months of age. Type II GH cells contain small (diameter 100–150 nm) and large secretory granules and are present after 6

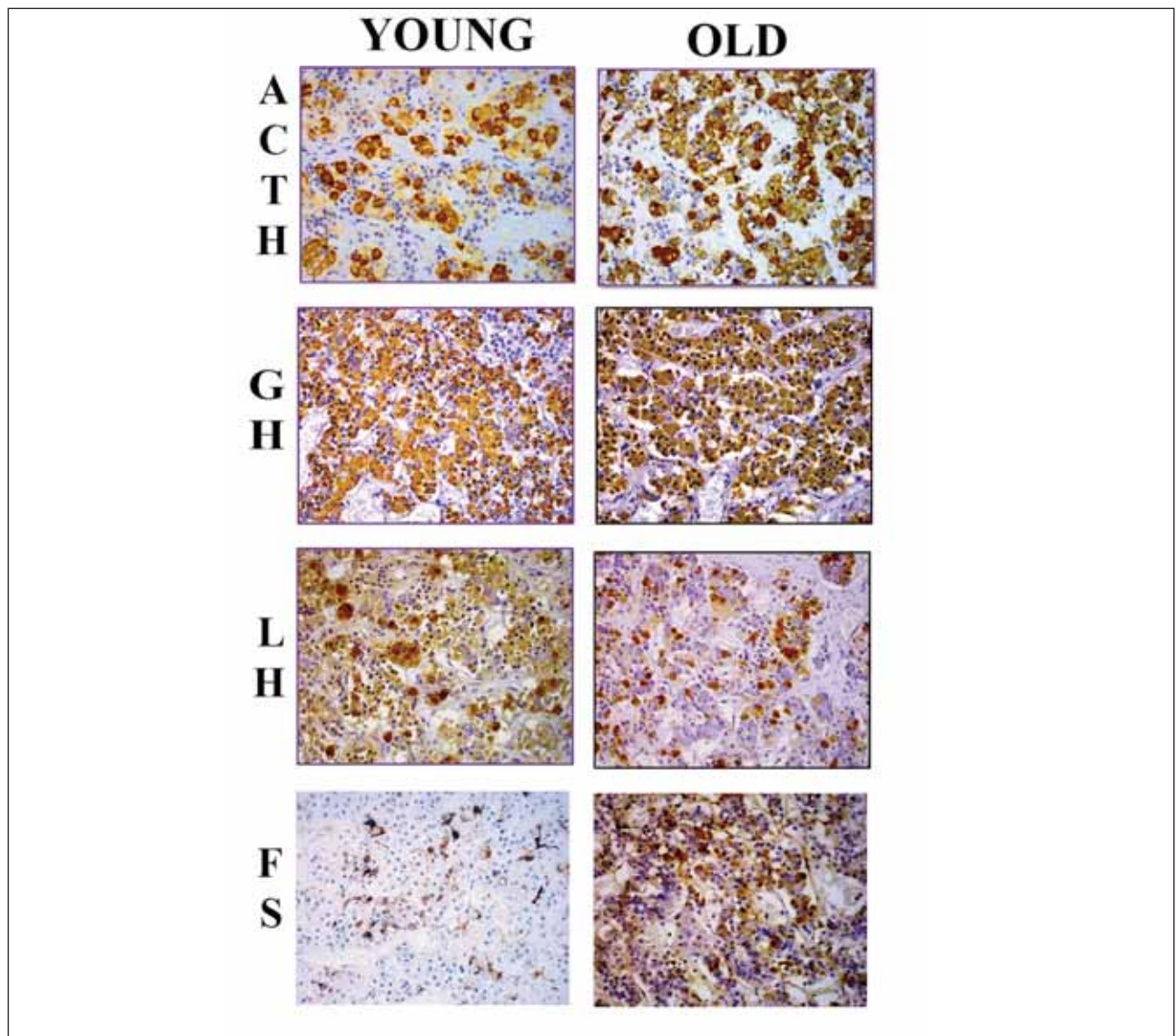


Figure 1 Representative micrograph of adrenocorticotrophic (ACTH), somatotrophic (GH), gonadotropic (LH) and folliculostellate (FS) cells in the pars distalis of the adenohypophysis in a young (44-year old) and an old (80-year old) man; Peroxidase–antiperoxidase (PAP) technique 40 × lens magnification.

months of age. Type III cells are characterized by small secretory granules and are immature GH type cells (47). The granular endoplasmic reticulum is well developed in GH cells. The Golgi complex is located near the nucleus and is moderately developed, near which there are vesicular and vascular structures. Elongated mitochondria are present in moderate numbers and are distributed around the nucleus (48).

In younger cadavers (41 years old), immunopositive *gonadotropic LH cells* were observed in the lateral wings of the adenohypophysis (49), oval or polygonal in shape and often with an irregularly positioned, euchromatic nucleus, immunopositive cytoplasm, brown in color, with numerous secretory granules (*Figure 1*) (6). In older cases, a reduced presence of blood vessels and interstitial fibrosis is

observed in the pituitary gland, and the distribution and presence of LH cells are similar to that of younger cases (12). Oval cells were larger than in younger cases, with an immunonegative eccentrically placed nucleus. The immunopositivity of old and young cadavers was similar (*Figure 1*) (18, 49). On electron microscopy, an eccentrically placed spherical nucleus can be seen, the Golgi zone is very dispersed, mitochondria are rare with lamellar cristae, poorly developed rough endoplasmic reticulum (RER) is detected (50). Numerous secretory granules are basophilic and can be smaller (diameter 200–250 nm), which are rare and larger, with a diameter of about 350–500 nm. These cells are among the largest cells in the pituitary gland (32).

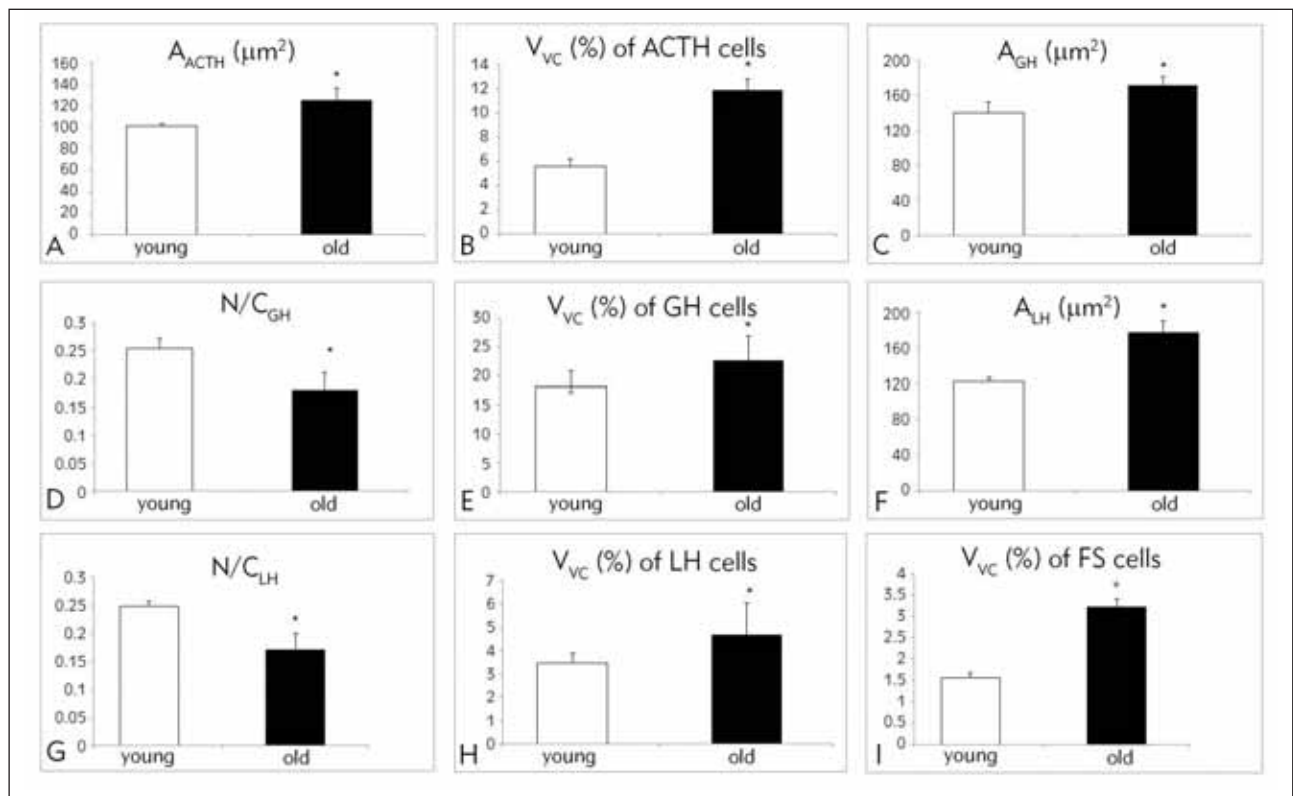


Figure 2 Graphical representation of the anterior pituitary gland parameters in the analyzed cases: correlation between age and area (A, C, F), volume density (B, E, H, I), nuclear-cytoplasmic ratio (D, G); A_{ACTH} – area of corticotropic cells; V_{ACTH} – volume density of corticotropic cells; A_{GH} – area of somatotropic cells; $(N/C)_{GH}$ – nuclear-cytoplasmic ratio of somatotropic cells; V_{GH} – volume density of somatotropic cells; A_{LH} – area of gonadotropic cells; $(N/C)_{LH}$ – nuclear-cytoplasmic ratio of gonadotropic cells; V_{LH} – volume density of gonadotropic cells; V_{VFS} – folliculostellate cells in dorsal pituitary. Results are expressed as means \pm SD; * $p < 0.05$ vs. young cadavers.

Folliculostellate cells are undifferentiated stem cells that, under specific conditions, can differentiate into different forms of pituitary cells (12). Immunohistologically labelled folliculostellate cells of the anterior pituitary gland in younger cadavers are star-shaped, with processes that stretch between endocrine cells. In the lateral wings, as well as in the mucoid wedge, the cells were rare and irregularly distributed in the lateral wings. The bodies of FS cells or their extensions are observed in the mucoid wedge, together with endocrine cells, inside the walls of the follicular formation. In the group of oldest cases, it was noticed that FS cells were irregular in shape, with a significant increase in their number both in the middle and in the lateral wings of the adenohypophysis, in addition to a further increase in their size compared to younger cases (14). Folliculostellate cells form a mesh structure that pervades the entire pituitary gland. In humans, these cells form a wall around pseudofollicular cells – they are small in volume, with scant cytoplasm. The ultrastructure of these cells is microfilamentous (4). Rare lipid droplets can be found in the cytoplasm of these cells. Golgi complex, gER are poorly developed. Mitochondria are small, rare and non-specific structures (4).

Morphometric characteristic of ACTH, GH, LH, and FS cells during aging

The area of ACTH cells in old cadavers significantly increased, by 12.1%, compared to young cases (Figure 2A) (9). The volume densities of the ACTH-positive cells statistically significantly increased in old cadavers, by 109.71%, compared to younger cadavers (10) (Figure 2B). These authors (10) showed a statistically significant positive correlation between the age of the examined cases and ACTH-positive cell volume density. Pavlović et al. (10) reported that linear regression analysis showed that the age of studied cases in their sample significantly predicted the volume density of anterior pituitary ACTH cells. Correlation analysis between the age and morphometric parameters of somatotropes showed that there was a significant positive correlation between age and area of somatotropes (28). Area and volume density of GH cells in old cadavers significantly increased, by 23.22% and 24.68%, respectively (Figure 2C, E), and the nuclear-cytoplasmic ratio of GH immunoreactive cells of the anterior pituitary decreased significantly with aging and was lower by 28.35% compared to younger cases

(Figure 2D) (14). Antić et al. (29) showed that the volume density of somatotropes of the anterior pituitary decreases with age. The area of gonadotrophic LH cells in old cadavers significantly increased, by 44.37% (Figure 2F), while the nuclear-cytoplasmic ratio decreased by 31.45% in relation to younger cases (Figure 2G). Volume density of gonadotrophic LH changed insignificantly, by 1.3 times, in comparison to younger cases (Figure 2H) (12). The volume density of FS cells in old cadavers was significantly increased, by 167.01% in the dorsal and by 105.76% in the ventral half of the adenohypophysis, compared to younger cases (Figure 2I) (14). Linear regression analysis showed that the volume density of FS cells in the examined cases is a statistically significant predictor of the nuclear-cytoplasmic ratio of GH immunoreactive cells (14). The results of the correlation analysis of the morphometric parameters of LH and FS cells showed that the volume density of FS cells is significantly positively correlated with the surface area of LH cells, while it is negatively correlated with the nuclear-cytoplasmic ratio of LH cells (Figure 2H).

Conclusions

Changes in the levels of ACTH, gonadotrophic LH, somatotrophic and folliculostellate cells of the adenohypophysis in men are statistically significantly more pronounced after the age of 70. It can be concluded that during the aging of men, the volume

density of ACTH, gonadotrophic LH, somatotrophic and folliculostellate cells of the adenohypophysis of men increases significantly. There is a statistically significant correlation between some of the analyzed morphometric parameters of gonadotrophic LH and somatotrophic cells of the adenohypophysis, which indicates the parallel occurrence of adaptation, i.e. compensatory mechanisms in these cells during aging. FS cells can influence the synthesis and release of ACTH, GH, LH cells and HPA activity through various mechanisms. Although the need to uncover hypothalamic-pituitary interactions is critical to understanding health and disease, the unavailability of human hypothalamic and pituitary tissues for research and the complexity of scientific techniques is a major problem for researchers.

Acknowledgements

The research described in this paper was financially supported by the Ministry of Science, Technological Development, and Innovation of the Republic of Serbia (Number of grants: 451-03-65/2024-03/200113), for which the authors are grateful.

Conflict of interest statement

All the authors declare that they have no conflict of interest in this work.

References

- Siddique K, Ager-Wick E, Fontaine R, Weltzien FA, Henkel CV. Characterization of hormone-producing cell types in the teleost pituitary gland using single-cell RNA-seq. *Sci Data* 2021; 8(1): 279. [DOI:10.1038/s41597-021-01058-8]
- Dorton A. The pituitary gland: embryology, physiology, and pathophysiology. *Neonatal Netw* 2000; 19(2): 9–17. [DOI:10.1891/0730-0832.19.2.9]
- Sheng JA, Bales NJ, Myers SA, Bautista AI, Roueifar M, Hale TM, et al. The Hypothalamic-Pituitary-Adrenal Axis: Development, programming actions of hormones, and maternal-fetal interactions. *Front Behav Neurosci* 2021; 14: 601939. [DOI:10.3389/fnbeh.2020.601939]
- Inoue K, Couch EF, Takano K, Ogawa S. The structure and function of folliculo-stellate cells in the anterior pituitary gland. *Arch Histol Cytol* 1999; 62(3): 205–18. [DOI:10.1679/aohc.62.205]
- Milošević V, Nestorović N, Negić N, Filipović B, Brkić B, Starčević V. Characteristics of the pituitary immunopositive ACTH cells in rat females after chronic exposure to constant light. *Jugosl Med Biohem* 2003; 22(1): 27–32. [DOI:10.2298/JMH0301027M]
- Stefaneanu L, Kovacs K. Endocrine System. Changes in Structure and Function of the Pituitary. In: Mohr U, Dungworth DL, Capen CC, editors. *Pathobiology of the Aging Rat, Vol II*. Washington, D.C.: ILSI Press, 1994: 173–91. [ISBN: 978-0944398203]
- Bahraman AG, Jamshidzadeh A, Keshavarzi M, Arabnezhad M-R, Mohammadi H, Mohammadi-Bardbori A. α -Melanocyte-stimulating hormone triggers melanogenesis via activation of the aryl hydrocarbon receptor pathway in B16F10 mouse melanoma cells. *Int J Toxicol* 2021; 40(2): 153–60. [DOI:10.1177/1091581820987548]
- Pilotto A, Custodero C, Maggi S, Polidori MC, Veronese N, Ferrucci L. A multidimensional approach to frailty in older people. *Ageing Res Rev* 2020; 60: 101047. [DOI:10.1016/j.arr.2020.101047]
- Pavlović M, Jovanović I, Pavlović S, Stojanović V, Živković V, Bakić M, et al. Morphometric study of connective tissue in the human pituitary during aging process. *Acta Fac med Naiss* 2013; 30(2): 79–84. [DOI:10.2478/v10283-012-0040-4]
- Pavlović M, Jovanović I, Ugrenović S, Stojanović V, Živković V, Kundalić B, et al. Human anterior pituitary's

- ACTH cells during the aging process: immunohistochemical and morphometric study. *Anat Sci Int* 2021; 96(2): 250–7. [DOI: 10.1007/s12565-020-00583-7]
11. van der Spoel E, Roelfsema F, van Heemst D. Relationships between 24-hours LH and testosterone concentrations and with other pituitary hormones in healthy older men. *J Endocr Soc* 2021; 5(9): 1–15. [DOI:10.1210/jendso/bvab075]
 12. Čukuranović-Kokoris J, Jovanović I, Ugrenović S, Stojanović V, Pavlović M, Kundalić B, et al. Immunohistochemical and morphometric study of adenohipophyseal gonadotropic cells in male cadavers of different ages. *Acta med Median* 2020; 59(4): 49–61. [DOI:10.5633/amm.2020.0407]
 13. Čukuranović-Kokoris J, Ajdžanović V, Pendovski L Ristić N, Milošević V, Dovenska M, et al. The effects of long-term exposure to moderate heat on rat pituitary ACTH cells: Histological and hormonal study. *Acta Vet (Beogr)* 2022; 72(1): 1–15. [DOI:10.2478/acve-2022-0001]
 14. Čukuranović-Kokoris J, Đorđević M, Jovanović I, Kundalić B, Pavlović M, Graovac I, et al. Morphometric analysis of somatotropic and folliculostellate cells of human anterior pituitary during ageing. *Srp Arh Celok Lek* 2022; 150(5-6): 274–81. [DOI:10.2298/SARH211214044C]
 15. Čukuranović Kokoris J, Ružić Z, Kanački Z, Stojanović S, Paraš S, Milošević V. Effects of vitamin C and early-age thermal conditioning on pituitary adreno-corticotrophic hormone cells in broilers chronically exposed to heat stress: an immunohistomorphometric and hormonal study. *Vet Res Forum* 2024; 15(3): 125–30. [DOI:10.30466/vrf.2023.2009320.3981]
 16. Keenan DM, Hefti JP, Veldhuis JD, Von Wolff M. Regulation and adaptation of endocrine axes at high altitude. *Am J Physiol Endocrinol Metab* 2020; 318(2): 297–309. [DOI:10.1152/ajpendo.00243.2019]
 17. Jovanović I, Ugrenović S, Ljubomirović M, Vasović LJ, Čukuranović R, Stefanović V. Folliculo-stellate cells - potential mediators of the inflammaging-induced hyperactivity of the hypothalamic-pituitary-adrenal axis in healthy elderly individuals. *Med Hypotheses* 2014; 83(4): 501–5. [DOI:10.1016/j.mehy.2014.08.018]
 18. Čukuranović Kokoris J, Jovanović I, Pantović V, Krstić M, Stanojković M, Milošević V, et al. Morphometric analysis of the folliculostellate cells and luteinizing hormone gonadotropic cells of the anterior pituitary of the men during the aging process. *Tissue Cell* 2017; 49(1): 78–85. [DOI:10.1016/j.tice.2016.11.006]
 19. Ajdžanović V, Trifunović S, Miljić D, Šošić-Jurjević B, Filipović B, Miler M, et al. Somatopause, weaknesses of the therapeutic approaches and the cautious optimism based on experimental ageing studies with soy isoflavones. *EXCLI J* 2018; 17: 279–301. [DOI:10.17179/excli2017-956]
 20. Kelberman D, Rizzoti K, Lovell-Badge R, Robinson IC, Dattani MT. Genetic regulation of pituitary gland development in human and mouse. *Endocr Rev* 2009; 30 (7): 790–829. [DOI:10.1210/er.2009-0008]
 21. Baisre de León A. Histopathology of the pituitary lesions. *Otolaryngol Clin North Am* 2022; 55(2): 265–85. [DOI:10.1016/j.otc.2021.12.003]
 22. Kaur H, Muhlhausler BS, Roberts CT, Gattford KL. The growth hormone-insulin-like growth factor axis in pregnancy. *J Endocrinol* 2021; 251(3): R23–39. [DOI:10.1530/JOE-21-0087].
 23. Rudman D, Kutner MH, Rogers CM, Lubin MF, Fleming GA, Bain RP. Impaired growth hormone secretion in the adult population: relation to age and adiposity. *J Clin Invest* 1981; 67(5): 1361–9. [DOI:10.1172/jci110164]
 24. Sattler FR. Growth hormone in the aging male. *Best Pract Res Clin Endocrinol Metab* 2013; 27(4): 541–55. [DOI:10.1016/j.beem.2013.05.003]
 25. Adamo ML, Farrar RP. Resistance training, and IGF involvement in the maintenance of muscle mass during the aging process. *Ageing Res Rev* 2006; 5(3): 310–31. [DOI:10.1016/j.arr.2006.05.001]
 26. Demiral M, Karaca MS, Unal E, Baysal B, Baran R, Demirbilek H, et al. A novel diagnostic tool for the evaluation of hypothalamic-pituitary region and diagnosis of growth hormone deficiency: pons ratio. *J Pediatr Endocrinol Metab* 2020; 33(6): 735–42. [DOI:10.1515/jpem-2019-0321]
 27. Milošević V, Brkić B, Velkovski S, Sekulić M, Lovren M, Starčević V, et al. Morphometric and functional changes of rat pituitary somatotropes and lactotropes after central administration of somatostatin. *Pharmacology* 1998; 57(1): 28–34. [DOI:10.1159/000028223]
 28. Akirov A, Masri-Iraqi H, Dotan I, Shimon I. The Biochemical diagnosis of acromegaly. *J Clin Med* 2021; 10(5): 1147. [DOI:10.3390/jcm10051147]
 29. Perrini S, Laviola L, Carreira MC, Cignarelli A, Natalicchio A, Giorgino F. The GH/IGF1 axis and signaling pathways in the muscle and bone: mechanisms underlying age-related skeletal muscle wasting and osteoporosis. *J Endocrinol* 2010; 205(3): 201–10. [DOI:10.1677/JOE-09-0431]
 30. Antić VM, Stefanović N, Jovanović I, Antić M, Milić M, Krstić M, et al. Morphometric analysis of somatotropic cells of the adenohipophysis and muscle fibers of the psoas muscle in the process of aging in humans. *Ann Anat* 2015; 200: 44–53. [DOI:10.1016/j.aanat.2015.01.006]
 31. Pamphlett R, Jew SK, Doble PA, Bishop DP. Elemental analysis of aging human pituitary glands implicates mercury as a contributor to the somatopause. *Front Endocrinol (Lausanne)* 2019; 10: 419. [DOI:10.3389/fendo.2019.00419]
 32. Veldhuis JD. Changes in pituitary function with ageing and implications for patient care. *Nat Rev Endocrinol* 2013; 9(4): 205–15. [DOI:10.1038/nrendo.2013.38]
 33. Childs GV. Cytochemical studies of multifunctional gonadotropes. *Microsc Res Tech* 1997; 39(2): 114–30. [DOI: 10.1002/(SICI)1097-0029(19971015)39:2<114::AID-JEMT3>3.0.CO;2-L]
 34. Grumbach MM. A window of opportunity: The diagnosis of gonadotropin deficiency in the male infant. *J Clin Endocrinol Metab* 2005; 90(5): 3122–7. [DOI:10.1210/jc.2004-2465]
 35. Seminara SB, Hayes FJ, Crowley WF Jr. Gonadotropin-releasing hormone deficiency in the human (idiopathic

- hypogonadotropic hypogonadism and Kallmann's syndrome): Pathophysiological and genetic considerations. *Endocr Rev* 1998; 19(5): 521–39. [DOI:10.1210/edrv.19.5.0344]
36. Uwaifo GI, editor. *The Human Hypothalamus: Anatomy, Dysfunction and Disease Management*. Cham: Humana Press, Springer Nature Switzerland AG, 2021: 528pp. [DOI:10.1007/978-3-030-62187-2]
37. Brioude F, Bouligand J, Trabado S., Francou B, Salenave S, Kamenicky P, et al. Non-syndromic congenital hypogonadotropic hypogonadism: Clinical presentation and genotype–phenotype relationships. *Eur J Endocrinol* 2010; 162(5): 835–51. [DOI:10.1530/EJE-10-0083]
38. Grumbach MM. The neuroendocrinology of human puberty revisited. *Horm Res* 2002; 57(Suppl 2): 2–14. [DOI:10.1159/000058094]
39. Bhasin S, Calof OM, Storer TW, Lee ML, Mazer NA, Jasuja R, et al. Drug Insight: testosterone and selective androgen receptor modulators as anabolic therapies for chronic illness and aging. *Nat Clin Pract Endocrinol Metab* 2006; 2(3): 146–59. [DOI:10.1038/ncpendmet0120]
40. Kaiser UB. Gonadotropin Hormones. In: Melmed S, editor. *The Pituitary*, 3ed. Academic Press 2011: 205–60. [DOI:10.1016/b978-0-12-380926-1.10007-0]
41. Roelfsema F, Liu PY, Takahashi PY, Yang RJ, Veldhuis JD. Dynamic interactions between LH and testosterone in healthy community-dwelling men: impact of age and body composition. *J Clin Endocrinol Metab* 2020; 105(3): e628–41. [DOI:10.1210/clinem/dgz246]
42. Herman-Bonert VS, Melmed S. Growth Hormone. In: Melmed S, editor. *The Pituitary*, 3ed. Academic Press 2011: 83–117. [DOI:10.1016/b978-0-12-380926-1]
43. Dudek P, Kozakowski J, Zgliczyński W. Late-onset hypogonadism. *Menopause Rev* 2017; 16(2): 66–9. [DOI:10.5114/pm.2017.68595]
44. Veldhuis JD, Keenan DM, Iranmanesh A, Takahashi PY, Nehra A. The Ensemble Male Hypothalamo-Pituitary-Gonadal Axis. In: Timiras PS, editor. *Physiological Basis of Aging and Geriatrics*, 4ed. CRC Press 2007: 185–203. [DOI:10.3109/9781420007091-17]
45. Perez-Castro C, Renner U, Haedo MR, Stalla GK, Arzt E. Cellular and molecular specificity of pituitary gland physiology. *Physiol Rev* 2012; 92(1): 1–38. [DOI:10.1152/physrev.00003.2011]
46. Nestorović N, Ristić N, Ajdžanović V, Trifunović S, Milošević V. Morphological and functional changes of pituitary GH and PRL cells following prolonged exposure of female rats to constant light. *Exp Appl Biomed Res* 2023; 24(3): 219–25. [DOI:10.2478/sjcr-2019-0063]
47. Takahashi S. Heterogeneity and development of somatotropes and mammatropes in the rat. *Zool Sci* 1992; 9: 901–24.
48. Kurosumi K. Ultrastructural immunocytochemistry of the adenohypophysis in the rat: a review. *J Electron Microscop Tech* 1991; 19(1): 42–56. [DOI:10.1002/jemt.1060190105]
49. Čukuranović-Kokoris J, Marković-Filipović J, Đorđević M, Kundalić B, Stojanović V, Trandafilović M, et al. Correlation analysis of pituitary luteinizing and somatotrophic cells in male cadavers during aging. *Acta Med Median* 2024; 63(1): 90–6. [DOI:10.5633/amm.2024.0110]
50. Horvath E, Kovacs K. Ultrastructural diagnosis of human pituitary adenomas. *Microsc Res Tech* 1992; 20(2): 107–35. [DOI:10.1002/jemt.1070200202]

Received: September 11, 2024

Accepted: November 06, 2024