

THE EFFECTS OF ERYTHROPOIETIN ON BACTERIAL TRANSLOCATION AND INFLAMMATORY RESPONSE IN AN EXPERIMENTAL INTESTINAL OBSTRUCTION MODEL IN RATS

UTICAJ ERITROPOETINA NA BAKTERIJSKU TRANSLOKACIJU I INFLAMATORNI ODGOVOR U EKSPERIMENTALNOM MODELU INTESTINALNE OPSTRUKCIJE KOD PACOVA

Murat Kapan, Akin Onder, Hatice Yuksel, Osman Evliyaoglu,
Ugur Firat, Recep Tekin, Mesut Gul, Ibrahim Aliosmanoglu

Department of General Surgery, Dicle University Medical Faculty Diyarbakir, Turkey

Summary

Background: Intestinal obstruction results in distortion of balance of antiinflammatory cytokines and release of oxidants, and also leads to bacterial translocation, sepsis and multiple organ failure. Asymmetric dimethylarginine is related to multiple organ failure as a new prognostic marker. Erythropoietin reduces the inflammatory response by decreasing the levels of proinflammatory cytokines and cytokine-induced apoptosis. In this study, we aimed to investigate the effectiveness of erythropoietin in reducing the severity of bacterial translocation and inflammatory response after intestinal obstruction and the relation between asymmetric dimethylarginine and inflammatory markers.

Methods: Forty Wistar albino rats (200–250 g) were divided into 4 groups as follows: Group 1 (Sham), only ileocaecal junction dissection; Group 2 (Erythropoietin), ileocaecal junction dissection and 3000 IU/kg erythropoietin subcutaneously; Group 3 (Intestinal Obstruction), complete ileal ligation; Group 4 (Intestinal Obstruction + Erythropoietin), complete ileal ligation and 3000 IU/kg erythropoietin subcutaneously. After 24 hours, the rats were sacrificed by taking blood from the heart for biochemical analyses. Peritoneal swab culture, liver, mesenteric lymph nodes, spleen and ileum were collected for microbiological and histopathological examinations.

Results: Erythropoietin reduced the secretion of inflammatory cytokines, oxidative damage and bacterial translocation, prevented the formation of inflammatory changes in the intestine, liver, spleen and mesenteric lymph nodes,

Kratak sadržaj

Uvod: Kao posledica intestinalne opstrukcije javlja se poremećaj ravnoteže antiinflamatornih citokina i oslobađanje oksidantata, a dolazi i do bakterijske translokacije, sepse i višestrukog otkazivanja organa. Asimetrični dimetilarginin dovodi se u vezu sa višestrukim otkazivanjem organa kao novi prognostički marker. Eritropoetin ublažava inflamatorni odgovor smanjivanjem nivoa proinflamatornih citokina i apoptoze izazvane citokinima. U ovoj studiji cilj je bio da istražimo efikasnost eritropoetina u pogledu smanjenja obima bakterijske translokacije i inflamatornog odgovora posle intestinalne opstrukcije, kao i odnos između asimetričnog dimetilarginina i inflamatornih markera.

Metode: Četrdeset albino pacova soja Wistar (200–250 g) podeljeno je u sledeće četiri grupe: Grupa 1, samo disekcija ileocekalnog spoja; Grupa 2 (Eritropoetin), disekcija ileocekalnog spoja i 3000 IU/kg eritropoetina supkutano; Grupa 3 (Intestinalna opstrukcija), kompletna ilealna ligacija; Grupa 4 (Intestinalna opstrukcija + eritropoetin), kompletna ilealna ligacija i 3000 IU/kg eritropoetina supkutano. Posle 24 časa, pacovi su žrtvovani uzimanjem krvi iz srca za biohemijske analize. Kulture peritonealnog brisa, jetre, mezenteričnih limfnih čvorova, slezine i ileuma uzete su za mikrobiološka i histopatološka ispitivanja.

Rezultati: Eritropoetin je smanjio lučenje inflamatornih citokina, oksidativno oštećenje i bakterijsku translokaciju, sprečio nastanak inflamatornih promena u crevima, jetri, slezini i mezenteričnim limfnim čvorovima i u značajnoj meri takođe

Address for correspondence:

Assist. Prof. Murat Kapan
Dicle University Medical Faculty
Department of General Surgery
21280, Diyarbakir, Turkey
Tel: +90 412.248-8001
Fax: +90 412.248-8523
e-mail: drmuratkapan@gmail.com

and also significantly prevented the formation of intestinal damage after intestinal obstruction ($p < 0.05$).

Conclusions: Asymmetric dimethylarginine levels did not differ between the groups. Erythropoietin may be useful to preserve from intestinal injury and related sepsis in patients with intestinal obstruction. Asymmetric dimethylarginine is not a suitable prognostic marker.

Keywords: erythropoietin, intestinal obstruction, bacterial translocation, asymmetric dimethylarginine

Introduction

Intestinal obstruction (IO) is a major problem for surgeons with the ratio of approximately 20% of emergency surgical diseases. Despite the development of treatment strategies, the mortality of mechanical IO is reported as still 5–20% (1). Beside the most important task of digestion and absorption, the small intestine creates a functional and mechanical barrier for the antigens, toxins and microorganisms (2). Under normal conditions, the small bowel contains very few bacteria, however the microbiological ecological balance is disrupted after IO (1). Bacterial growth as a result of disrupted ecological balance, immune dysfunction induced by deterioration of the balance of pro- and anti-inflammatory cytokines and release of oxidants after mucosal barrier dysfunction accelerate the development of bacterial translocation (3). Increased intestinal permeability leads to the development of systemic inflammatory response, infection, sepsis and multiple organ failure (MOF) (2) by increasing the translocation of bacteria and their products to the peritoneal space, mesenteric lymph nodes (MLNs), liver, spleen and systemic circulation which are normally sterile (4).

Interleukin-6 (IL-6), which is one of the pro-inflammatory cytokines appearing after the oxidative and inflammatory stress, is an important parameter in determining the level of inflammatory damage (5). Other important markers of inflammatory response are Tumor Necrosis Factor- α (TNF- α) and Interleukin-1 β (IL-1 β) (6). In addition, C-reactive protein (CRP) is both an acute-phase reactant and an important marker of systemic inflammatory response (7).

Recently, asymmetric dimethylarginine (ADMA) has been reported to be associated with MOF, liver failure and the severity and incidence of intensive care unit mortality in a concentration-dependent manner, and is also reported to be directly related to MOF or a new important indicator (5).

Erythropoietin (EPO) reduces the inflammatory response by decreasing the levels of proinflammatory cytokines and cytokine-induced apoptosis along with trophic effects on the bowel. In addition, recent data have suggested that EPO supports angiogenesis, reduces oxidative stress and accelerates wound healing (2).

sprečio nastanak intestinalnih oštećenja posle intestinalne opstrukcije ($p < 0,05$).

Zaključak: Nivoi asimetričnog dimetilarginina nisu se razlikovali između grupa. Eritropoetin može biti koristan za sprečavanje intestinalnih oštećenja i sepse kod pacijenata sa intestinalnom opstrukcijom, dok asimetrični dimetilarginin nije odgovarajući prognostički marker.

Ključne reči: eritropoetin, intestinalna opstrukcija, bakterijska translokacija, asimetrični dimetilarginin

In this study our aim was to investigate the effectiveness of EPO, microbiologically, biochemically and histopathologically, in reducing the severity of bacterial translocation and inflammatory response emerging as a result of mechanical IO, and we also aimed to investigate the correlation between inflammatory markers and ADMA, as an inflammatory marker.

Materials and Methods

Chemical

Erythropoietin was purchased from Sigma (E5627–Erythropoietin human recombinant, expressed in Chinese hamster ovary cells, lyophilized powder, cell culture tested, ~ 100,000 units/mg protein) and dissolved in phosphate buffer saline.

Animals

Forty Wistar albino rats, each weighing 200–250 g, were included in the study at the Dicle University Health Sciences Application and Research Center. The experimental manipulations and surgical operations in this study were approved by the Committee of Experimental Animals of Dicle University. All experimental procedures complied with the guide for the Care and Use of Laboratory Animals. Rats were housed in cages and allowed free access to standard rat chow and water before the experiments under standard conditions in an air-conditioned room with 12 h light and dark cycles, at constant temperature (22 ± 2 °C). The animals were fasted overnight the day before surgery, but had access to water.

Forty Wistar albino rats were divided into four groups ($n=10$): Group 1 (Sham, S), only ileocaecal junction dissection was performed; Group 2 (Erythropoietin, EPO), ileocaecal junction dissection was performed and 3000 IU/kg EPO was given subcutaneously; Group 3 (Intestinal Obstruction, IO), ileocaecal junction dissection with ileal ligation; Group 4 (Intestinal Obstruction + Erythropoietin, IO + EPO), ileocaecal junction dissection with ileal ligation and 3000 IU/kg EPO was given subcutaneously.

Surgical Procedure

Rats were anesthetized with 50 mg/kg ketamine hydrochloride (Ketalar®, Parke Davis, Eczacıbasi,

Istanbul, Turkey) and 10 mg/kg xylazine (Rompun®, Bayer AG, Leverkusen, Germany) via intramuscular injection for all surgical procedures. For laparotomy, a midline incision was performed under sterile conditions and the ileocaecal junction was dissected. After 2 mL saline were given into the peritoneal area, the abdominal wall was closed in one layer in the groups S and EPO. In the groups IO and IO+EPO, after laparotomy and midline incision, the ileocaecal junction placed in the middle and distal ileum was ligated with 3-0 silk suture at 1 cm proximal to the caecum, obstructing the passage but not inhibiting the circulation of the vessels. Then 2 mL saline were given into the peritoneal area and the abdominal wall was closed in one layer (7).

After a period of 24 hours (3), the rats were anesthetized and sacrificed by taking blood from the heart for biochemical analyses. Under sterile conditions, a thoracoabdominal midline incision was performed immediately. After opening the abdomen, peritoneal swab culture was taken for microbiological analyses and a 1 mL blood sample was taken from the inferior vena cava. Liver, MLNs, spleen and ileum samples were collected for microbiological and histopathological examinations. Serum was obtained from the centrifugation of the blood and stored at -80 °C until analyses. The tissues for histopathological evaluation were put into plastic containers with 10% formaldehyde solution after washing with saline for removing the foreign tissue residues and blood.

Biochemical analyses

Total oxidant activity (TOA), total antioxidant capacity (TAC), paraoxonase (PONX), TNF- α , IL-6, IL-1 β , CRP and ADMA analyses were performed in the blood samples.

TOA of supernatant fractions was determined using a novel automated measurement method, developed by Erel (8). Oxidants present in the sample oxidize the ferrous ion-o-dianisidine complex to ferric ion. The oxidation reaction is enhanced by glycerol molecules, which are abundantly present in the reaction medium. The ferric ion makes a colored complex with xylenol orange in an acidic medium. The color intensity, which can be measured spectrophotometrically, is related to the total amount of oxidant molecules present in the sample. The assay is calibrated with hydrogen peroxide and the results are expressed in terms of $\mu\text{mol H}_2\text{O}_2$ Equiv/L.

TAC of supernatant fractions was determined using also a novel automated measurement method developed by Erel (9). In this method, the hydroxyl radical is produced, which is the most potent biological radical. In the assay, ferrous ion solution, which is present in Reagent 1, is mixed with hydrogen peroxide, which is present in Reagent 2. The sequentially produced radicals, such as brown colored dianisidiny radical cation, produced by the hydroxyl radical, are

also potent radicals. Using this method, the antioxidative effect of the sample against the potent free radical reactions, which is initiated by the produced hydroxyl radical, is measured. The results are expressed as mmol Trolox Eq/L.

Serum PONX levels were measured spectrophotometrically by a modified Eckerson method (9). Initial rates of paraoxon hydrolysis (O,O-diethyl-O-p-nitrophenylphosphate; Sigma Chemical Co. London, UK) were determined by measuring liberated p-nitrophenol at 405 nm at 37 °C. The results are expressed as U/L (10).

TNF- α , IL-6 and IL-1 β (Diasource; Nivelles, Belgium), ADMA (Immundiagnostik; Bensheim, Germany) and CRP (DRG; NJ, USA) levels were measured using commercially available ELISA kits.

Microbiological assay

Blood samples were obtained from the heart and cultured aerobically and anaerobically using the BacTec™ Peds battles (Becton-Dickinson Diagnostic Inc., Sparks, MD, USA). Identification was realized by the BD-Phoenix 100 TM system. Peritoneal swab and positive cultures were plated out on blood agar, eosin methylene blue (EMB) agar, chocolate agar and Sabouraud-dextrose agar. At the same time, MLNs, spleen and liver were removed and placed in sterile glass bottles containing sterile brain-heart infusion media. The bottles were re-weighed and tissue homogenates were prepared in 2 mL brain-heart infusion using a sterile mortar and pestle. A portion (0.1 mL) of each homogenate was cultured on blood agar, EMB agar, and chocolate agar and Sabouraud-dextrose agar. All agar plates were examined after 24 h and 48 h of incubation at 37 °C. The incidence of bacterial translocation was calculated by determining the number of rats with positive bacterial culture divided by the total number of rats studied.

Histopathological assessment

Ileal segment, MLNs and liver tissues were put into the 10% formalin solution in paraffin blocks and prepared by slicing 4- μm sections. Tissues stained with hematoxylin-eosin and standard protocols were applied.

Ileal segment, MLNs and liver samples were examined for the grade of inflammatory cell infiltrate, and the ileal segments were also examined for the ileal mucosal injury score by an expert pathologist, using light microscopy (Nikon ECLIPSE 80i). As concordant to the literature, the changes were graded as follows; Grade 0, no changes; Grade 1, mild changes; Grade 2, moderate changes; Grade 3, severe changes (1, 4). In addition, all tissue samples were examined under light microscopy by staining Giemsa for the evaluation of bacterial translocation.

Table I Biochemical results of the groups.

Groups	S (n=10)	EPO (n=10)	IO (n=10)	IO+EPO (n=10)
PONX (U/L)	35.54 ± 8.52	71.11 ± 13.06 ^a	18.68 ± 4.26 ^a	36.91 ± 6.78 ^b
TAS (mmol Trolox Eq/L)	0.72 ± 0.06	1.50 ± 0.26 ^a	0.71 ± 0.09	1.16 ± 0.35 ^{a, b}
TOS (μmol H ₂ O ₂ Equiv/L)	12.14 ± 1.21	16.93 ± 6.22 ^a	33.52 ± 10.58 ^a	14.44 ± 7.37 ^b
ADMA (μmol/L)	2.35 ± 0.80	3.26 ± 1.29	2.34 ± 0.95	2.52 ± 0.93
TNF-α (pg/mL)	1.93 ± 0.86	1.84 ± 1.23	7.59 ± 1.72 ^a	1.41 ± 0.47 ^b
IL-6 (pg/mL)	31.25 ± 8.45	26.87 ± 5.86	65.83 ± 20.44 ^a	32.63 ± 7.90 ^b
IL-1β (pg/mL)	0.47 ± 0.11	0.23 ± 0.10 ^a	1.62 ± 0.59 ^a	0.79 ± 0.64 ^c
CRP (mg/L)	30.46 ± 4.64	28.27 ± 4.14	165.26 ± 41.06 ^a	85.50 ± 15.68 ^{a, b}

Data were given as Mean ± SD. ^a Significantly different when compared with S group ($p \leq 0.001$). ^b Significantly different when compared with IO group ($p \leq 0.001$). ^c Significantly different when compared with IO group ($p = 0.005$).

Table II Histopathological grading of the groups.

Groups	S (n=10)	EPO (n=10)	IO (n=10)	IO+EPO (n=10)
Liver inflammation score	0.11 ± 0.31	0.11 ± 0.31	1.34 ± 0.47 ^a	0.5 ± 0.47 ^b
MLN inflammation score	1.5 ± 0.53	1.7 ± 0.67	2.5 ± 0.53 ^a	1.8 ± 0.63 ^b
Ileum inflammation score	1 ± 0	1 ± 0	2.59 ± 0.51 ^a	1.66 ± 0.47 ^b
Ileal mucosal damage score	0 ± 0	0 ± 0	1.29 ± 0.66 ^a	0.66 ± 0.47 ^b

Data were given as Mean ± SD. ^a Significantly different when compared with S group ($p < 0.05$). ^b Significantly different when compared with IO group ($p < 0.05$).

Statistical analysis

Statistical analysis was performed by SPSS for Windows 11.5 (SPSS Inc., Chicago, IL, USA). Data were expressed as the mean ± SD (standard deviation) values for biochemical values. Groups were compared by using the nonparametric Kruskal-Wallis test. Mann-Whitney U test was used for binary comparisons. A P value of less than 0.05 was considered significant.

Results

All animals survived throughout the experimental procedures. Biochemical results are summarized in *Table I*. IO is significantly associated with oxidative stress. Serum PONX, TAC and TOA levels were different among the groups. PONX activity was lower in

the IO group than the S group and higher in the IO+EPO group than the IO group. However, TAC levels did not differ significantly in the IO group; EPO treatment supported TAC levels in the EPO and IO+EPO groups. TOA levels were increased in the IO group compared to the S group, and the treatment with EPO significantly prevented the increase of TOA levels in the IO+EPO group.

Also, the inflammatory cytokines (TNF-α, IL-6, IL-1β) and CRP were increased after IO. In the IO+EPO group, all these cytokines were significantly decreased when compared with the IO group. There was no significant difference in ADMA levels between the groups.

The histopathological grading of the liver, MLNs and ileum is summarized in *Table II*. There was no difference between the S and EPO group scores. Inflam-

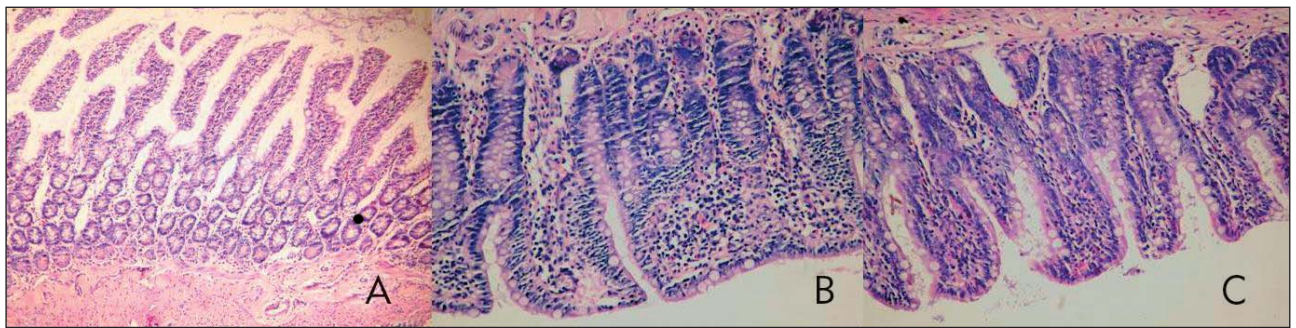


Figure 1 The effects of EPO on ileal inflammation and mucosal injury after IO evaluated by histological examination. A: In group Sham, minimal mucosal inflammation (H&E stain, x100). B: In group IO, subtotal villous atrophy and mild epithelial degenerative changes in the intestinal mucosa with severe inflammation and edema (H&E stain, x200). C: In group IO+EPO, mild to moderate inflammation and edema in the mucosa with minimal epithelial degenerative changes (H&E stain, x200).

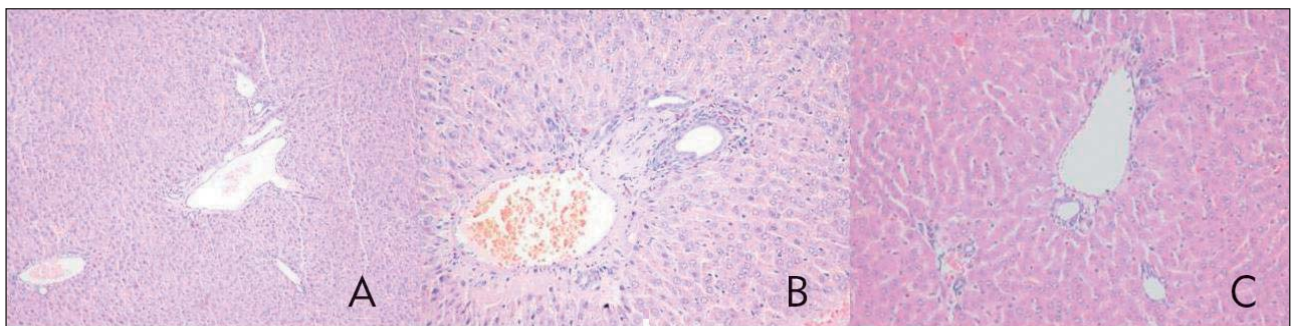


Figure 2 The effects of EPO on liver inflammation after IO evaluated by histological examination. A: In group Sham, mild edema in the liver parenchyma (H&E stain, x100). B: In group IO, moderate portal inflammation and edema in the liver (H&E stain, x200). C: In group IO+EPO, mild parenchymal inflammation of the liver (H&E stain, x200).

Table III Microbiological culture results of the groups.

Groups	S (n=10)	EPO (n=10)	IO (n=10)	IO+EPO (n=10)
Blood culture (c/d)	0/10	1/10	8/10 ^a	1/10 ^b
Liver culture (c/d)	0/10	1/10	9/10 ^a	3/10 ^b
Spleen culture (c/d)	1/10	1/10	8/10 ^a	2/10 ^b
Peritoneal culture (c/d)	3/10	2/10	9/10 ^a	2/10 ^b

Data were given as Mean \pm SD. ^a Significantly different when compared with S group, ($p < 0.05$); ^b significantly different when compared with IO group ($p < 0.05$).

mation scores of the liver ($p < 0.001$), MLNs ($p = 0.03$) and ileum ($p < 0.001$) were higher in the IO group than the S group. In addition, the ileal mucosal damage score was higher in the IO group ($p < 0.001$). The inflammation scores of the liver ($p = 0.003$), MLNs ($p = 0.035$) and ileum ($p = 0.003$) were lower in the IO+EPO group when compared with the IO group, and also the ileal mucosal damage score ($p = 0.043$) was lower in the IO+EPO group (Figure 1 and 2).

The culture results are summarized in Table III as the number of rats with positive bacterial culture divided by the total number of rats. There was no difference between the groups S and EPO. Blood ($p = 0.002$), liver ($p < 0.001$), spleen ($p = 0.007$), MLNs ($p = 0.007$), and peritoneal ($p = 0.023$) cultures were significantly positive in the IO group when compared with the S group. However, in the IO+EPO group positive cultures were decreased, suggesting the EPO

treatment significantly reduced the positive cultures of blood ($p=0.007$), liver ($p=0.023$), spleen ($p=0.023$), MLNs ($p=0.023$) and peritoneal cultures ($p=0.007$).

Discussion

The present study, using a rat model, has demonstrated that protective effects in the small intestine and remote organs after IO were obtained after the treatment with EPO. In IO, with the disruption of ecological balance and involvement of the immune system, the bowel becomes a source for the reservoir of systemic infection and MOF via bacterial translocation. As a result of the increased intestinal permeability, microorganisms may be translocated to the systemic circulation, MLNs and liver (11, 12). Terminal obstruction of the ileum has been shown to create more bacterial translocation (13). So, in this study, we obstructed the terminal ileum, and both histopathological and microbiological assessments showed the results of IO and bacterial translocation.

IO was significantly associated with bacterial overgrowth, oxidative stress and inflammatory response. IO increased oxidative stress in a manner similar with the one in the study reported by El-Awady et al. (3). There were significant inflammatory changes in the liver and ileal mucosal tissues after small bowel obstruction in the IO group when compared with the S group. These changes were attenuated significantly with the EPO treatment in the liver, spleen and ileum mucosal tissues except MLNs. EPO is a strong antioxidant (6), and it has been reported that EPO increased the activity of antioxidant enzymes and decreased lipid peroxidation (14, 15). Furthermore, Bakan et al. (16) suggested that there was a direct relationship between the levels of antioxidant enzymes and lipid peroxidation. In this study, EPO treatment increased TAC and PONX levels and decreased TOA levels. These findings demonstrated that EPO reduced the oxidative injury, and this was confirmed with histopathology.

Bacteria can be detected in the MLNs within 6 hours of IO, while bacteria spread to the liver, spleen and blood after 24 hours of IO (11). Cevikel et al. (7) demonstrated the occurrence of bacterial translocation in the samples of MLNs, liver, and blood in 67% of animals after IO. We determined, after 24 hours of IO, that the samples of MLNs, liver and peritoneum had positive culture results in 90% and spleen had positive culture in 80% of rats in the IO group. Positive hemocultures were observed in 80% of rats in the IO group. However, no evidence of bacterial translocation was observed in animals in either control group, S and EPO. This difference in bacterial translocation rates between the experimental and control groups was statistically significant ($P<0.05$).

EPO has cytoprotective effects on many cells and tissues beyond its hematopoietic activity, and these have been studied widely. Exogenous administration of EPO in animal models attenuates ischemic brain and spinal cord injury (17), acute kidney injury (18) and ischemia reperfusion-induced lung injury (19). EPO mediates reconditioning (ischemic tolerance) and specifically limits the destructive role of TNF- α and other proinflammatory cytokines in the heart, brain, kidney, and other tissues. The therapeutic effects of EPO for tissue protection are very wide in experimental models, showing effectiveness when administered before, during, or after an insult and raising optimism for high clinical potential (20). In this study, EPO was given to rats after the IO. Although there are various studies for understanding the signaling pathways responsible for EPO's tissue-protective actions that are similar to those employed for erythrocyte maturation, much work remains to be carried out because EPO has now emerged as a multifunctional tissue-protective cytokine (21–23).

Previous studies have reported the effects of EPO against I/R injury in the small intestine (24). Also, EPO decreased the serum levels of TNF- α and IL-6 at 6 hours after I/R injury, which are the major proinflammatory cytokines upregulated in I/R injury (25). Hu et al. (26) have reported that EPO treatment significantly reduced the gene expression of major proinflammatory cytokines (TNF- α , IL-6 and IL-1 β), while Hojman et al. (27) revealed the increasing of proinflammatory cytokines after the administration of EPO in a human model of acute systemic low-grade inflammation. In addition, Villa et al. (28) revealed that the antiinflammatory effect of EPO was related with the direct effect on inflammatory cells rather than the inhibition of cytokines secretion. In this study, TNF- α , IL-6 and IL-1 β levels were lower in the EPO treatment group. For that reason, we believe that EPO treatment attenuates the proinflammatory cytokine levels due to the reduction of proinflammatory cytokines secretion.

Plasma CRP is an acute-phase protein and increases markedly with acute invasive infections. CRP concentrations are correlated with the severity of inflammation and tissue injury (21). Cevikel et al. (7) have reported that CRP levels increase with the severity of bacterial translocation in acute IO. Similarly, our study demonstrated significant increases in CRP levels in the IO group 24 h after the onset of obstruction. The proinflammatory cytokines and mediators of the acute phase reactions are correlated with the surgical intervention, and the surgery-based nature of this model makes it difficult to differentiate the effects of surgical trauma from IO (22). Therefore, CRP levels in our sham-operated control group were higher than those in the EPO control group. El-Awady et al. (3) have suggested that the CRP is a reliable test of bacterial translocation during IO, and it is a predictor of vascular compromise and bacterial translocation se-

verity. In our study, the CRP levels were decreased due to the effects of EPO on the inflammatory response.

Plasma ADMA concentration has been reported to be a strong and independent risk factor for intensive care unit mortality, and hepatic dysfunction is the most prominent determinant of ADMA concentration in critically ill patients (23). It is reported to be directly related to MOF and correlated with IL-6. Also, ADMA concentration is dependent on the kidney and liver functions (5). Bacterial translocation, caused by IO, creates a source for systemic infection and MOF (29). So, we decided that ADMA may be a novel prognostic marker in the monitoring of patients with IO and therefore the correlation between ADMA concentration and IO was investigated. But, there was no significant difference between the groups, and this can be attributed to the normal liver and kidney functions. Based on these results, ADMA is not a useful parameter in the monitoring of patients with IO.

References

- Demirkan A, Aksoy M, Kuzu MA, Toruner A. The effects of indomethacine on intestinal permeability and bacterial translocation in intestinal obstruction. *Journal of Ankara University Faculty of Medicine* 2006; 59: 119–27.
- Theodorou D, Aggeli P, Markogiannakis H, Skourolia-kou M, Archontovasilis F, Kastanidou O, Burnetas A, Xiromeritou V, Katsaragakis S. Protection of intestinal permeability in the perioperative period. *J Clin Gastroenterol* 2009; 43: 500.
- El-Awady SI, El-Nagar M, El-Dakar M, Ragab M, Elnady G. Bacterial translocation in an experimental intestinal obstruction model. C-reactive protein reliability? *Acta Cir Bras* 2009; 24: 98–106.
- Akçay MN, Capan MY, Gündoğdu C, Polat M, Oren D. Bacterial translocation in experimental intestinal obstruction. *J Int Med Res* 1996; 24: 17–26.
- Van Hoorn EC, Van Middelaar-Voskuilen MC, Van Limpt CJP, Lamb KJ, Bouritius H, Vriesema AJM, Van Leeuwen PAM, Van Norren K. Preoperative supplementation with a carbohydrate mixture decreases organ dysfunction-associated risk factors. *Clin Nutr* 2005; 24: 114–23.
- Mori S, Sawada T, Okada T, Kubota K. Erythropoietin and its derivative protect the intestine from severe ischemia/reperfusion injury in the rat. *Surgery* 2008; 143: 556–65.
- Cevikel MH, Özgün H, Boylu S, Demirkiran AE, Aydın N, Sari C, Erkus M. C-reactive protein may be a marker of bacterial translocation in experimental intestinal obstruction. *ANZ J Surg* 2004; 74: 900–4.
- Erel O. A new automated colorimetric method for measuring total oxidant status. *Clin Biochem* 2005; 38: 1103–11.
- Erel O. A novel automated method to measure total antioxidant response against potent free radical reactions. *Clin Biochem* 2004; 37: 112–19.
- Eckerson HW, Romson J, Wyte C, La Du BN. The human serum paraoxonase polymorphism: identification of phenotypes by their response to salts. *Am J Hum Genet* 1983; 35: 214–27.
- Aldemir M, Köko lu OF, Geyik MF, Büyükbayram H. Effects of octreotide acetate and *Saccharomyces boulardii* on bacterial translocation in an experimental intestinal loop obstruction model of rats. *Tohoku J Exp Med* 2002; 198: 1–9.
- Alexander JW, Boyce ST, Babcock GF, Gianotti L, Peck MD, Dunn DL, Pyles T, Childress CP, Ash SK. The process of microbial translocation. *Ann Surg* 1990; 212: 496–510.
- Deitch EA, Bridges WM, Ma JW, Ma L, Berg RD, Specian RD. Obstructed intestine as a reservoir for systemic infection. *Am J Surg* 1990; 159: 394–401.
- Kumral A, Gonenc S, Acikgoz O, Sonmez A, Genc K, Yilmaz O, Gokmen N, Duman N, Ozkan H. Erythropoietin increases glutathione peroxidase enzyme activity and decreases lipid peroxidation levels in hypoxic-ischemic brain injury in neonatal rats. *Biol Neonate* 2005; 87: 15–18.
- Garipardic M, Bakan V, Davutoglu M, Sayar H, Kuruta EB. Oxidative stress and protective effect of erythropoietin on methotrexate-induced esophageal damage. *J Pediatr Hematol Oncol* 2010; 32: 108–112.
- Bakan V, Garipardic M, Okumu M, Ciralik H, Atli Y, Ozbag D, Tolun FI. The protective effect of erythropoietin on the acute phase of corrosive esophageal burns in a rat model. *Pediatr Surg Int* 2010; 26: 195–201.

17. Maiese K, Li F, Chong ZZ. Erythropoietin in the brain: can the promise to protect be fulfilled? *Trends Pharmacol Sci* 2004; 25: 577–83.
18. Sharples EJ, Yaqoob MM. Erythropoietin in experimental acute renal failure. *Nephron Exp. Nephrol* 2006; 104: e83–88.
19. Wu H, Ren B, Zhu J, Dong G, Xu B, Wang C, Zheng X, Jing H. Pretreatment with recombinant human erythropoietin attenuates ischemia-reperfusion-induced lung injury in rats. *Eur J Cardiothorac Surg* 2006; 29: 902–7.
20. Brines M, Cerami A. Discovering erythropoietin's extra-hematopoietic functions: biology and clinical promise. *Kidney Int* 2006; 70: 246–50.
21. Johnson HL, Chiou CC, Cho CT. Applications of acute phase reactants in infectious diseases. *J Microbiol Immunol Infect* 1999; 32: 73–82.
22. Bolke E, Jehle PM, Graf M, Baier A, Wiedeck H, Steinbach G, Storck M, Orth K. Inflammatory response during abdominal and thyroid surgery: a prospective clinical trial on mediator release. *Shock* 2001; 16: 334–9.
23. Nijveldt RJ, Teerlink T, Van Der Hoven B, Siroen MPC, Kuik DJ, Rauwerda JA, Van Leeuwen PAM. Asymmetrical dimethylarginine (ADMA) in critically ill patients: high plasma ADMA concentration is an independent risk factor of ICU mortality. *Clin Nutr* 2003; 22: 23–30.
24. Guneli E, Cavdar Z, Islekel H, Sarioglu S, Erbayraktar S, Kiray M, Sokmen S, Yilmaz O, Gokmen N. Erythropoietin protects the intestine against ischemia/reperfusion injury in rats. *Mol Med* 2007; 13: 509–17.
25. Schmeding M, Neumann UP, Boas-Knoop S, Spinelli A, Neuhaus P. Erythropoietin reduces ischemia-reperfusion injury in the rat liver. *Eur Surg Res* 2007; 39: 189–97.
26. Hu L, Yang C, Zhao T, Xu M, Tang Q, Yang B, Rong R, Zhu T. Erythropoietin Ameliorates Renal Ischemia and Reperfusion Injury via Inhibiting Tubulointerstitial Inflammation. *J Surg Res* 2011; 1–7 (doi:10.1016/j.jss.2011.06.035).
27. Hojman P, Taudorf S, Lundby C, Pedersen BK. Erythropoietin augments the cytokine response to acute endotoxin-induced inflammation in humans. *Cytokine* 2009; 45: 154–7.
28. Villa P, Van Beek J, Larsen AK, Gerwien J, Christensen S, Cerami A, Brines M, Leist M, Ghezzi P, Torup L. Reduced functional deficits, neuroinflammation, and secondary tissue damage after treatment of stroke by nonerythropoietic erythropoietin derivatives. *J Cereb Blood Flow Metab* 2007; 27: 552–63.
29. Reis E, Kama NA, Aksoy M, Sahin M, Korkusuz P, Kulacoglu S, Tekeli A, Ors U. The effects of vitamin E and ocreotide on bacterial translocation in rats with intestinal obstruction. *T Klin J Gastroenterohepatol* 1996; 7: 67–75.

Received: February 8, 2012

Accepted: March 15, 2012